

# Periparturient Haemorrhage

Haemorrhage during foaling affects 2–3% of mares and is responsible for 40% of deaths related to parturition. The cause is rupture of a major blood vessel, most frequently the uterine artery. All mares are at risk of haemorrhage during foaling but older mares that have foaled previously can be considered at greatest risk. During successive pregnancies blood flow and vessel diameter increases, resulting in increased load upon the arterial walls. The average number of foals produced by a mare prior to suffering from periparturient haemorrhage is 8, but this can vary greatly. During parturition uterine contractions and foetal movements may induce vascular rupture. The occurrence of dystocia, uterine prolapse or torsion appears to increase the risk of vessel rupture. Haemorrhage may occur before, during or after parturition, but the most common time period is twenty-four hours after parturition.

## DIAGNOSIS

Clinical signs which may be displayed by a mare suffering from periparturient haemorrhage, include:

- Discomfort or colic in a late pregnant/ foaling. This may include lying down, shifting weight from one limb to another, rolling, pawing the ground, muscle fasciculation's and flank watching.
- Inappetence
- Increased heart rate- often greater than 100 beats per minute
- Increased respiratory rate
- Sweating
- Reduced body temperature
- Very pale mucous membranes

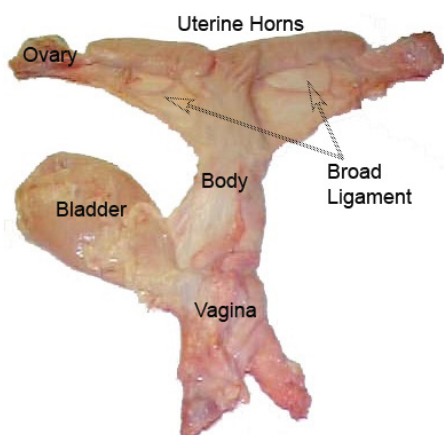


Fig 1. Anatomy of the broad ligament

Unfortunately haemorrhage into the abdomen is often rapidly fatal, due to the circulatory shock. However, in some horses the haemorrhage is contained within the broad ligament, a wide sheet of tissue that connects the uterus and ovaries to the roof of the abdomen and the walls of the pelvis.

The bleed may stop itself as a blood clot develops within the broad ligament and seals the source of haemorrhage. Stretching of the broad ligament can be painful; therefore these mares often continue to show signs of trembling or even colic. The haematoma formed can often be up to 20–30cm in size. The diagnosis can be confirmed by cautious rectal palpation and ultrasonography. Great care must be taken when performing manual rectal examination of a mare suspected of having a broad ligament haemorrhage as rupture of the broad ligament can lead to collapse and death and palpation of the haematoma may elicit signs of pain.

When haemorrhage is not contained within the broad ligament blood rapidly accumulates in the abdomen. This can be identified by ultrasonography of the abdomen and sampling of the peritoneal fluid, which characteristically will have a high red blood cell count.

## TREATMENT

Obtaining a diagnosis and rapidly instigating treatment is essential to increase chance of survival. Treatment is supportive as surgical access to the equine reproductive tract is limited. The mainstay of treatment is keeping the mare calm and comfortable whilst providing treatment to speed up blood clotting

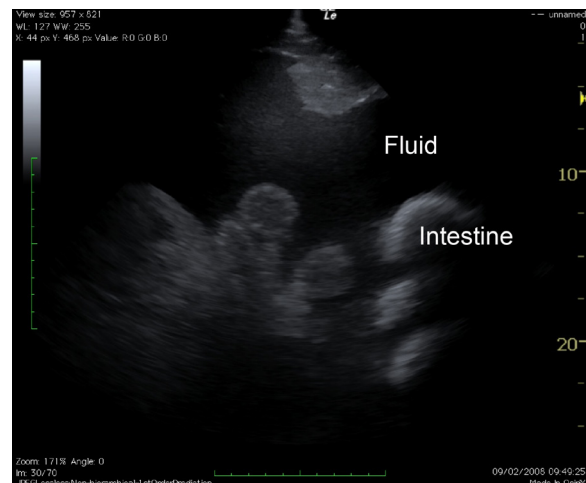


Fig 2. Ultrasound image showing free blood in the abdomen

and support circulation. Foals should not be removed from the mare unless the mare is showing severe signs of colic and the foal is at risk of injury.

Medication administered may include:

- Clot stabilising drugs such as tranexamic acid – this drug is used very widely and successfully in human critical care. Its benefits have not yet been critically evaluated in horses but it appears to be safe, and at least on theoretical grounds is a logical emergency intervention.
- Anti-inflammatories and painkillers to keep the mare calm and comfortable.
- Sedatives may be used to keep the mare calm, quiet and reduce blood pressure so that the bleeding ceases as quickly as possible.
- Antimicrobials to reduce the risk of secondary infections occurring.
- Blood transfusion – Mares that have lost more than twenty five percent of their blood volume or those who have had very rapid haemorrhage may benefit from a blood transfusion to restore circulating blood levels.

Following severe haemorrhage, significant compromise can occur to other body systems because of circulatory failure, disruption of blood flow to vital organs and lack of oxygen in the tissues. The heart and kidneys are particularly at risk and these mares may need a high level of intensive care in order to get over these sorts of multi-system problems.

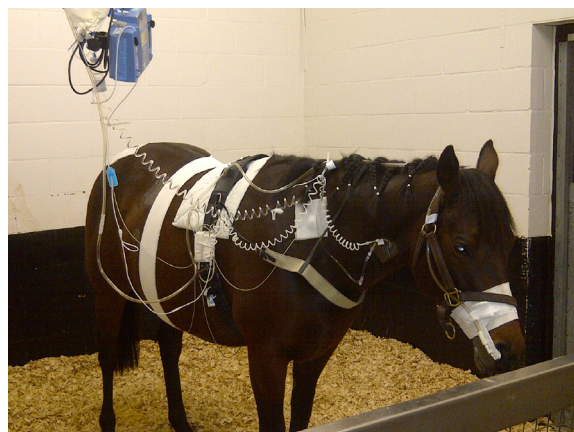

Fig 3. A mare receiving intravenous fluid nutrition and intranasal oxygen. An ECG has been attached to the mare with a surcingle so that her heart function can be monitored.

## OUTCOME

Haematomas that remain contained within the broad ligament gradually become firmer, increase in density and reduce in size over several months. Some studies suggest that there may be an increased likelihood of recurrence of vascular rupture with fatal haemorrhage at subsequent parturition. However more recent evidence suggests that affected mares are generally fertile, and once the haematoma has regressed sufficiently in size, they may deliver foals without recurrence of haemorrhage. One study has shown that 49% of mares that survive periparturient haemorrhage will produce at least one more foal.