

Cervical Vertebrae Stenotic Myelopathy (Wobblers Syndrome)

KEY POINTS

- Cervical Vertebrae Stenotic Myelopathy (CVSM), commonly known as Wobblers Syndrome, is estimated to occur in around 2-3% of Thoroughbreds.
- CVSM is characterized by abnormal gait in the front and/or hind limbs with a varying degree of incoordination and weakness.
- The onset of clinical signs is typically between six months to three years, although mature horses may also become affected.
- There are two main anatomical characteristics associated with the disorder: static narrowing of the cervical (neck) vertebrae canal through which runs the spinal cord and dynamic compression of the spinal cord by the cervical vertebrae.

DEVELOPMENT OF CVSM

Affected horses typically demonstrate very fast growth and are also likely to be predisposed to developmental orthopaedic disease. Developmental orthopaedic disease of the appendicular skeleton such as physitis (growth plate inflammation), joint effusion, osteochondrosis (OCD) and flexural limb deformities occur more frequently in horses with CVSM. Although a direct link between OCD and CVSM has not been identified, the frequency of occurrence of these two conditions suggests that their pathophysiology is similar.

The precise role of genetics in the condition remains to be clarified but it is likely that specific genes represent risk factors for the condition but these may need to be combined with acquired risk factors in order for CVSM to develop. A high plane of nutrition, rapid growth and abnormal biomechanical forces through the limbs are possible contributors to the development of CVSM.

Abnormal growth patterns lead to a spinal canal that is narrowed, or which becomes narrow when the neck moves and the vertebrae move relative to each other. This, in turn, leads to compression of the spinal cord. The spinal cord carries the nerves from the brain to the limbs and with CVSM deficits in this process result in spastic paresis. This term is used to describe a particular form of muscle weakness that is characterised by jerky

movement. The spinal cord also carries nerves from the limbs to the brain, which sends information on limb position. The unconscious awareness of limb, head and body position is called proprioception. Ataxia (incoordination) can occur when there is damage in the brain (cerebellar or vestibular ataxia) but in horses, the third form, sensory ataxia, due to damage to the spinal cord and loss of proprioception, is the most common, not least because CVSM is such a common cause of neurological deficits in horses.

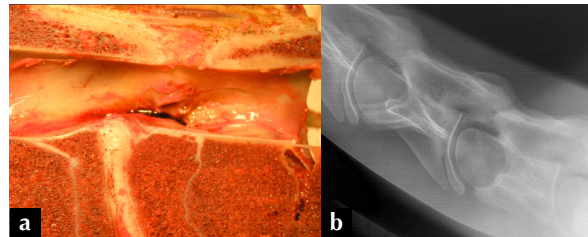


Fig 1: (a) This specimen illustrates how the spinal canal can become narrowed when the cervical vertebral bones grow in an abnormal shape. (b) The narrowing of the spinal canal is also visible in a radiograph of the same horse.

COMMON CLINICAL SIGNS ASSOCIATED WITH CVSM

Horses with CVSM demonstrate three characteristic clinical signs: symmetrical ataxia, spasticity and weakness behind with possible involvement of the forelimbs. Often the first apparent clinical signs in a horse with CVSM will come about either during ridden work or walking. These signs consist of stumbling and toe dragging, which are a result of weakness. Horses with prolonged clinical signs of CVSM may have toes or shoes that are chipped, worn or squared off as a result of toes dragging.

An affected horse at rest may have a base-wide stance and delayed corrective response when its limbs are positioned in abnormal locations. Horses with spinal ataxia can have a truncal sway at walk. Tight circling reveals both circumduction (swinging the outer hind limbs very wide) and pivoting on the inside limb, known as posting.



Fig 2: This horse's toes are squared off because he has been dragging them.

More severely affected horses may present with overreach wounds/interference wounds over the heel bulbs and inside aspect of the forelimbs. Other horses may present with a stiff neck, show reluctance to rise and fall easily and may just appear lazy.

In the assessment of each horse the degree of ataxia is given a grade according to the Modified Mayhew System.



Fig 3: This horse with CSVM has excessive circumduction, an exaggerated hindlimb action when turned in a tight circle.

GRADE OF ATAXIA	CLINICAL SIGNS
GRADE 0	<ul style="list-style-type: none"> • Normal
GRADE 1	<ul style="list-style-type: none"> • Minimal neurological deficits noted with normal gait. • Require proprioceptive/manipulative tests – crossing legs, tail sways, tight circles, blindfolding, and backing in order to demonstrate any clinical signs.
GRADE 2	<ul style="list-style-type: none"> • Mild abnormal gait seen at walk (walks like a patient that has been sedated). • More obvious response to proprioceptive/manipulative tests • Patients can be performing successfully but when asked they have trouble with lead changes, going down hills at a trot or gallop, stumble, require a lot of leg to maintain propulsion, knuckle over when stopping, bunny hop behind when cantering or drag hind toes at a trot.
GRADE 3	<ul style="list-style-type: none"> • Easy to see at walk and very obvious at a canter but do not fall.
GRADE 4	<ul style="list-style-type: none"> • Very ataxic, fall especially in tight circles or backing. • Usually refuse to go any faster than a walk.
GRADE 5	<ul style="list-style-type: none"> • Recumbent, may not become sternal even with encouragement.

TYPES OF CVSM

CVSM can be split into three main types depending on when clinical signs are seen in relation to the positioning of the neck.

TYPE OF CVSM	PRESENTATION	NECK VERTEBRAE AFFECTED
TYPE ONE	<ul style="list-style-type: none"> • Vertebral column is fixed in a flexed position at the site of the malarticulation/malformation of the cervical vertebrae, causing compression of the spinal cord • Usually present from birth but occurs very infrequently 	<ul style="list-style-type: none"> • These cases generally arise from the second and third cervical vertebrae.
TYPE TWO	<ul style="list-style-type: none"> • Symmetrical overgrowth of the articular processes of the cervical vertebrae result in spinal cord compression during flexion of the neck only • Mostly occur in sucklings and weanlings 	<ul style="list-style-type: none"> • These cases generally arise from the upper and middle cervical vertebrae.
TYPE THREE	<ul style="list-style-type: none"> • Asymmetrical overgrowth of one articular process results in spinal cord compression either directly as a result of bony proliferation or indirectly through soft tissue swelling. • Most commonly affects mature horses but may be seen in young horses. 	<ul style="list-style-type: none"> • Areas of neck most commonly affected include cervical vertebrae number five, six and seven.

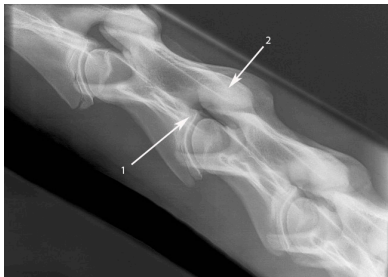

Fig 4: This radiograph shows flare of the caudal vertebral body growth plate (1) and extension of the dorsal laminae (2). These are 2 of the changes in the shape of the cervical vertebral bones that lead to compression of the spinal cord.

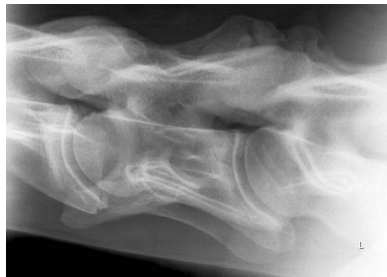

Fig 5: This radiograph shows severe arthritis and abnormal ossification of the articular process in a horse with long-standing CVSM. The lower of the 2 joints that are illustrated is particularly severely affected.

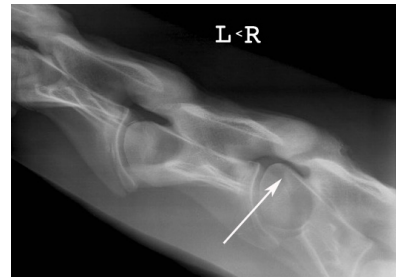

Fig 6: This radiograph shows marked malalignment of the neck bones (arrow).

DIAGNOSIS

A presumptive diagnosis is obtained by a combination of a detailed history from owners and trainers, breed and age of the horse and an in depth neurological exam performed by your vet.

Radiographic examination of the cervical (neck) vertebrae will often reveal some malformations/malarticulation the cervical vertebrae leading to the clinical signs of ataxia and paresis.

Several lateral radiographs are taken in order to image the entire length of the cervical spine. Five characteristic bony malformations of cervical vertebrae may be seen in horses with CVSM.

- 1: Flare of the caudal vertebral body growth plate (epiphysis)
- 2: Abnormal ossification of the articular processes
- 3: Malalignment between adjacent vertebrae
- 4: Extension of the dorsal laminae
- 5: Degenerative joint of the articular processes (OCD or Osteoarthritis)

It is important to note that compressive lesions can develop at vertebral sites not affected by bony malformation thus may not be picked up on routine radiographs. It can be helpful to measure the diameter of the spinal canal and calculate a ratio of the spinal canal to the adjacent bone, in order to correct for any magnification of the images. There are various measurement techniques available but one of the simplest is to measure the diameters of the canal and body of the vertebrae at the front of each bone; the ratio should be greater than 50%.

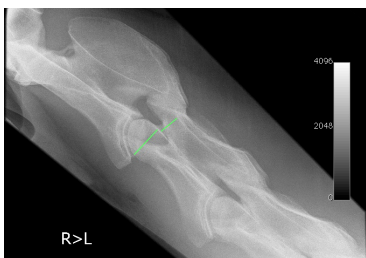

Fig 7: In this horse, the canal diameter is 2.3 cm while the vertebral body is 3.9 cm, thus the ratio is well over 50% indicating that there is no compression.

Myelography may be helpful to pin point the exact site of compression, which is essential if surgery is being considered. Myelography involves injecting a contrast agent into the subarachnoid space surrounding the spinal cord. The contrast agent outlines the spinal cord and shows areas of compression.

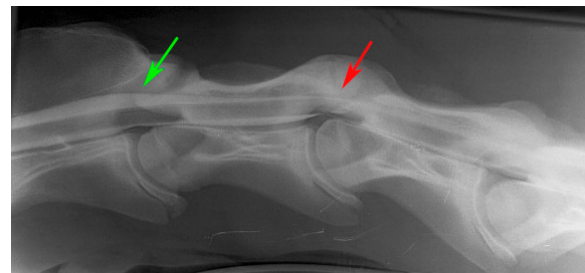


Fig 8: For myelography, a contrast agent is injected into the space around the spinal cord which shows as a white line. Notice the difference between the width of the contrast band at the normal joint (green arrow) and the affected joint (red arrow).

An alternative advanced diagnostic technique, Computerised Tomography (CT) can also be used to detect both severity and location of any malformation or compressive lesions affecting the spinal cord. Currently, CT units are available that provide images of the upper neck joints, but for typical Thoroughbred size, it can be difficult to image the lower neck joints.

TREATMENT

Medical Management

In those horses with acute compressive lesions, treatment include anti-inflammatory medication to reduce swelling surrounding the spinal cord and thus reducing the compression acting on the spinal cord itself. Horses that have moderate degenerative joint changes on radiographs and relatively mild ataxia may benefit from having corticosteroids and hyaluronate injected into the intervertebral joints to reduce soft tissue swelling and reduce further bony proliferation. These cases tend to be greater than 3 years of age.

Box rest coupled with a dietary change aimed at reducing protein and carbohydrate intake, thus reducing growth rate in younger horses less than a year of age, may slow development of CVSM. It is important that any diet should include the minimum requirement of essential nutrients including vitamin E and selenium that are essential for the health of the nervous tissue.

Surgical Management

Surgery involves placing a metal basket across the unstable joint(s) to stabilise the area and allow the bones and spinal canal to remodel. The most appropriate candidates for surgical treatment are young horses with only one or two myelographic lesions with mild to moderate clinical signs with no other concurrent disease. It is important to note that the outcome of any surgery performed may not be known for a considerable length of time, up to a year in some cases. Most surgeons report improvement of cases graded 1 – 2, so horses with severe ataxia are not suitable candidates.

Prognosis

80% of patients can improve at least one ataxia grade after treatment.

54% can improve two grades or more with successful surgery.

33% of horses perform athletically as a result of successful treatment.

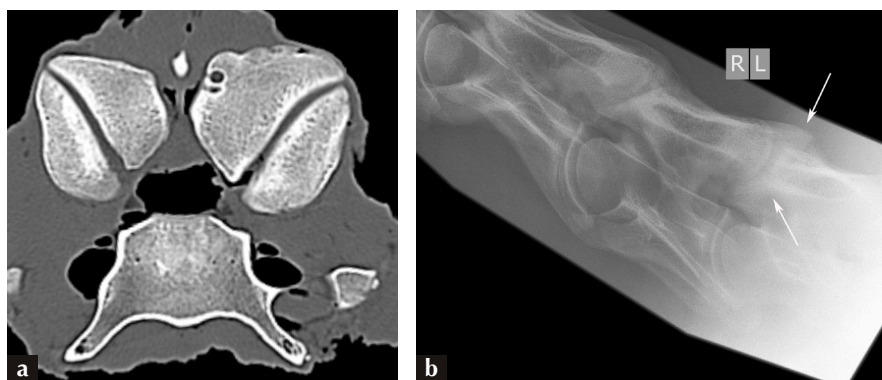


Fig 9: (a) CT provides a slice image so that the internal anatomy of the spinal column can be seen whereas. (b) a radiograph is a 2 dimensional representation of the 3 dimensional structure and while in a lateral image changes from top to bottom may be obvious, compression across the spinal canal from left to right is difficult to appreciate. In this horse, the CT image shows how the joint on one side of the neck is much larger than the other and is compressing the cord transversely. The corresponding radiograph shows the joint is large, but this detail is not evidence. The problem is that with most CT units, which are designed for humans, it is impossible to obtain images of the lower neck joints, which are a common site for pathology. This CT scan was performed as part of a post-mortem exam.